Surg Radiol Anat (2004) 26: 384–391
DOI 10.1007/s00276-004-0240-4

ORIGINAL ARTICLE

J. R. Ortale · L.C. Borges Keiralla

Anatomy of the portal branches and the hepatic veins in the caudate lobe of the liver

Received: 30 June 2003 / Accepted: 2 February 2004 / Published online: 5 August 2004

Abstract The objective of this study was to analyze the caudate portal branches and their relationships with the hepatic caudate veins and propose a new nomenclature for the caudate branches based on their territory of distribution. We realized the fine dissection of the veins of the caudate lobe in 40 human livers fixed and preserved in formalin. In 15/40 (37.5%) cases there was a single branch to the caudate lobe. In 25/40 (62.5%) cases there was more than one branch, with a posterior caudate branch in 20/40 (50%) cases, an anterior caudate branch in 15/40 (37.5%) cases, a left caudate branch in 14/40 (35%) cases, and a right caudate branch in 8/40 (20%) cases. The most frequent combination detected (11/40, 27.5% of cases) was that of the posterior and anterior branches. The venous drainage of the caudate lobe and its papillary process was provided by the superior caudate hepatic vein in 23/40 (57.5%) cases, by the middle caudate vein in 35/40 (87.5%) cases (which was the only vein in 12/35 cases), and by the inferior caudate vein in 16/40 (40%) cases. In 11/40 (12.5%) cases there were accessory caudate veins, which emptied into the left and intermediate hepatic veins. The portal branches and the hepatic veins related to the caudate process were studied. In conclusion, the new nomenclature analyzes more precisely the distribution of the caudate portal branches.

Keywords Caudate lobe · Liver segment · Portal vein · Hepatic veins · Anatomy

J. R. Ortale (✉) · L.C. Borges Keiralla
Faculdade de Medicina,
Pontifícia Universidade Católica de Campinas,
Av. John Boyd Dunlop s/n,
Jardim Ipaussurama, CEP 13059-900
Campinas, (SP), Brasil
E-mail: ortalejr@uol.com.br
Tel.: +55-193-7298600 / 2722305
Fax: +55-193-2728961

Introduction

Knowledge about the distribution of the portal branches and of venous drainage through the hepatic pathways in the caudate lobe of the liver is indispensable for examination and treatment of hepatic diseases such as Budd-Chiari syndrome and tumors of the extrahepatic bile ducts, which commonly involve the caudate lobe and require its excision [9, 11, 12, 13, 14, 15].

Today, the Anatomical Terminology [5] adopts the numeration of the hepatic segments described by Couinaud [3], with the caudate lobe corresponding to the posterior or I segment. To define the deep limit of the caudate lobe (anterior surface of the lobe) and separate it from the paracaval segment, we followed the method of Couinaud [4]. This author considered the caudate lobe (segment I) to be located anteriorly and to the left of the inferior vena cava, and the paracaval segment (segment IX) to be located anteriorly and to the right of the inferior vena cava both in the interval between the intermediate and right hepatic veins and close to the latter. The caudate process joins segments I and IX and continues to the right with the prerenal eminence [12].

Di Dio [6] pointed out that the caudate lobe is the only segment where there is coincidence and not interdigitation of the two systems of vascularization by the portal vein and of drainage by the hepatic veins, simultaneously corresponding to the portal segment (I) and to the hepatovenous segment (I). According to Heloury et al. [9], the caudate lobe is a liver segment independent of the right and left liver and is the only one directly draining into the inferior vena cava.

Elias and Sherrick [7] reported that the superior and inferior caudate veins usually converged before emptying on the left wall of the inferior vena cava, at times emptying separately, with a venula draining the caudate process and emptying into the inferior vena cava.

The objective of the present study was to analyze and propose a new nomenclature for the distribution of the

caudate portal branches from their origin in the portal vein to their termination inside the caudate lobe, and their relationship with the hepatic caudate veins, as well as their emptying in the retrohepatic segment of the inferior vena cava divided into 12 areas.

Material and methods

Forty human livers obtained at autopsy at the Forensic Medicine Institute of Campinas and at the Laboratory of Anatomy of PUC–Campinas, conserved in 5% formalin solution, were submitted to fine dissection of the caudate portal branches from their origin in the hepatic portal vein to their termination in the caudate lobe, and of the caudate hepatic veins up to their opening into the inferior vena cava or into the major hepatic veins. The lobe was considered to consist of two parts: 1) caudate lobe proper and papillary process, and 2) caudate process.

The portal branches distributed in the caudate lobe and its papillary process were denominated as follows according to their vascularization bed: branch of the caudate lobe, when there was only one branch, and posterior, anterior, left and right caudate branches.

The hepatic veins of the caudate lobe and its papillary process were classified as superior, middle and inferior according to the site of emptying into the respective third of the retrohepatic segment of the vena cava. To this end, the retrohepatic segment of the vena cava was sectioned longitudinally at the point of transition between the right and the posterior walls. The inner wall of the retrohepatic segment of the vena cava was then divided into 12 areas comprising four columns (posterior, left, anterior, and right) and three rows (superior, middle and inferior) which were numbered from 1 to 12 starting from the posterior superior area (area 1), followed by the superior left area (area 2), and so forth until the right inferior area (area 12).

Fig. 1 shows a schematic presentation of the distribution of the portal branches for the vascularization of the caudate lobe and its papillary process and the drainage of these territories by the caudate hepatic veins.

For the study of the caudate process, the structure was divided into left and right portions along a vertical plane passing through the midpoint of the anterior contour of the vena cava. The portal branches were denominated a branch of the caudate process when there was only one branch, and left and right caudate branches, and the hepatic veins were classified as a vein of the caudate process, when single, and left and right veins of the caudate process.

The number, diameter (range and mean ± SD), and origin of the caudate vessels and the relationship between the caudate portal branches and the caudate hepatic veins were analyzed as well as the opening of the caudate hepatic veins and the distance from their ostium to the ostium of the common trunk of the intermediate and left hepatic veins. The paracaval vessels adjacent to segment I were also studied. Some anatomical specimens representative of the normal type and its variations were photographed and schematically drawn.

Results

For presentation of the results, we shall divide the veins into caudate portal branches and caudate hepatic veins: 1) of the caudate lobe with its papillary process, 2) of the caudate process, and 3) of the paracaval segment. Finally, we will add 4) accessory hepatic caudate veins, tributaries of the intermediate hepatic vein (IHV), left hepatic vein (LHV), and common trunk IHV-LHV.

Portal ramification in the caudate lobe proper and its papillary process

In 15/40 (37.5%) cases there was a single portal branch for the caudate lobe proper and for its papillary process, which was denominated caudate lobe branch (Fig. 1, Fig. 2). This branch originated from the left branch of the portal vein in 9/15 cases and from the posterior contour of the portal vein in 6/15 cases.

In 25/40 (62.5%) cases, there were two or three caudate portal branches, with the occurrence of four types of branches, denominated posterior, anterior, left, and right caudate branches according to their vascularization bed. The posterior caudate branch partially or totally vascularized the posterior part of the caudate lobe and its papillary process and, even if it occasionally sent branches toward the anterior portion, was predominantly posterior and was present in 20/25 cases, predominantly originating (11/20 cases) from the left branch of the portal vein. The anterior caudate branch was partially or totally distributed toward the anterior or deep part of the caudate lobe and papillary process and, even if it occasionally sent branches toward the posterior portion, was predominantly anterior and was present in 15/25 cases, and its most common origin was from the left branch of the portal vein (12/15 cases). In 2/15 cases this branch contributed to the vascularization of the left medial hepatic segment (segment IV). The left and right branches vascularized the corresponding portion of the lobe and its papillary process, and when a posterior branch and/or an anterior branch were present, they complemented the vascularization of the posterior or anterior portion of the caudate lobe on the corresponding side. The left caudate branch was present in 14/25 cases and originated from the left branch of the portal vein, whereas the right caudate branch was present in 8/25 cases and originated from the right branch of the portal vein, from the portal vein itself, or from the left branch of the portal vein.

In 19/25 cases there were two branches, which were the posterior and anterior branches in 11/19 (Fig. 1, Fig. 3), the right and left branches in 4/19 (Fig. 1,

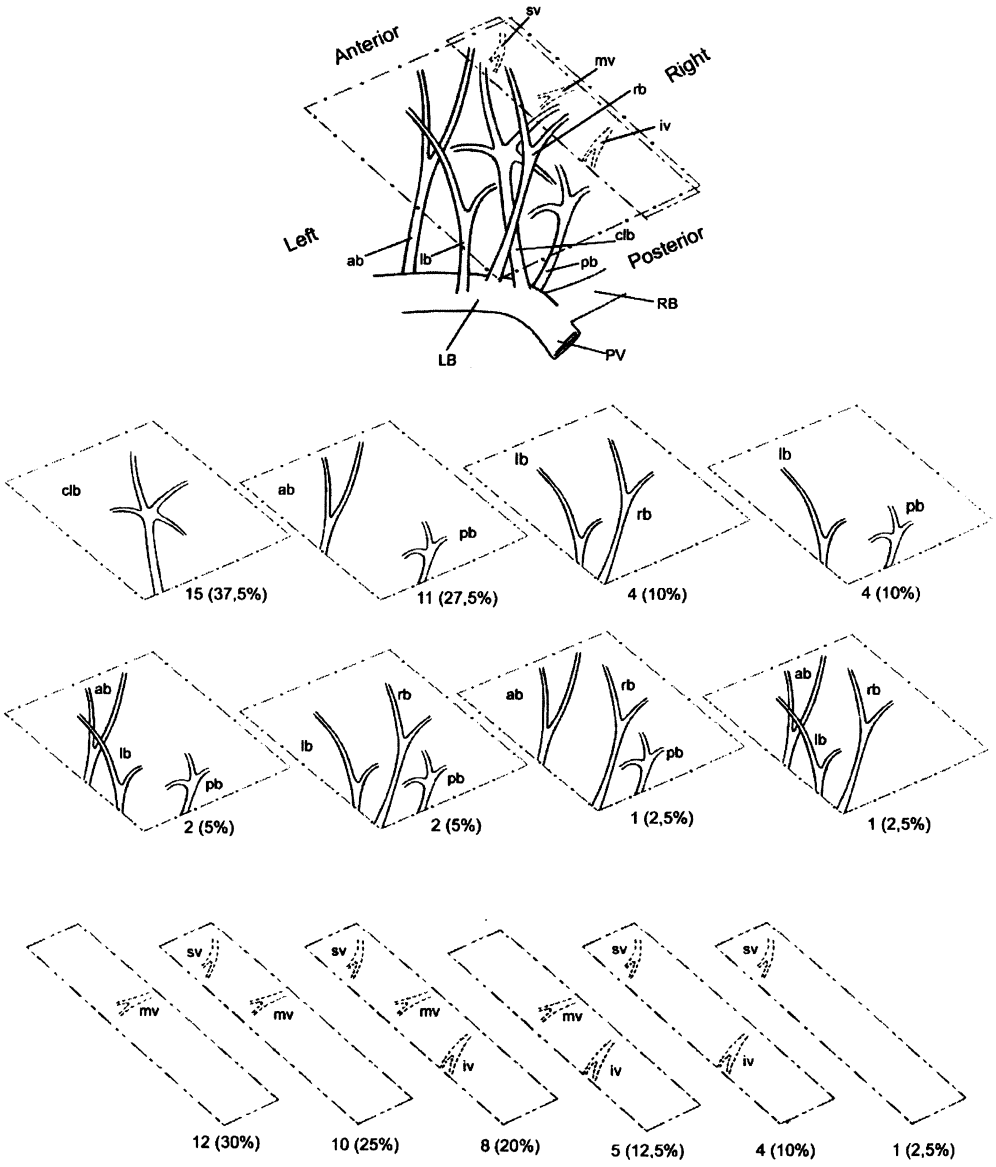

Fig. 1 Distribution of the caudate portal branches to the caudate lobe and its papillary process and drainage of these territories by the caudate hepatic veins (*PV* portal vein; *LB*, *RB* left and right branches of PV; *clb* branch of the caudate lobe; *ab*, *pb*, *lb*, *rb* anterior, posterior, left, and right branches of the portal veins to the respective parts of the caudate lobe)

Fig. 4), and the posterior and left branches in 4/19. Three branches were present in 6/25 cases; the posterior, anterior, and left branches in 2/6; the posterior, right, and left branches in 2/6; the posterior, anterior, and right branches in 1/6; and the anterior, right, and left branches in 1/6.

With respect to the relationship of the caudate portal branches with the caudate hepatic veins, in 11/15 cases in which there was only the branch of the caudate lobe, the portal branches resulting from its ramification were located superficially in relation to the hepatic veins, both on the posterior or visceral surface and on the anterior or deep surface of the lobe and its papillary process. In the cases in which there were several caudate portal branches, their relationships with the hepatic veins were predominantly as follows: the posterior and right caudate branches were predominantly superficial on the posterior surface, while the anterior and left caudate branches were predominantly superficial on the anterior surface.

Table 1 lists the number, diameter, origin, and relationship with the hepatic caudate veins of the caudate portal branches distributed toward the caudate lobe and its papillary process.

Hepatic veins of the caudate lobe proper and its papillary process

The caudate lobe proper was divided into three regions: superior, middle, and inferior, with the last one including the papillary process. According to the localization of their emptying ostia into the superior, middle, and inferior thirds of the retrohepatic segment of the inferior vena cava, the caudate veins were classified into three

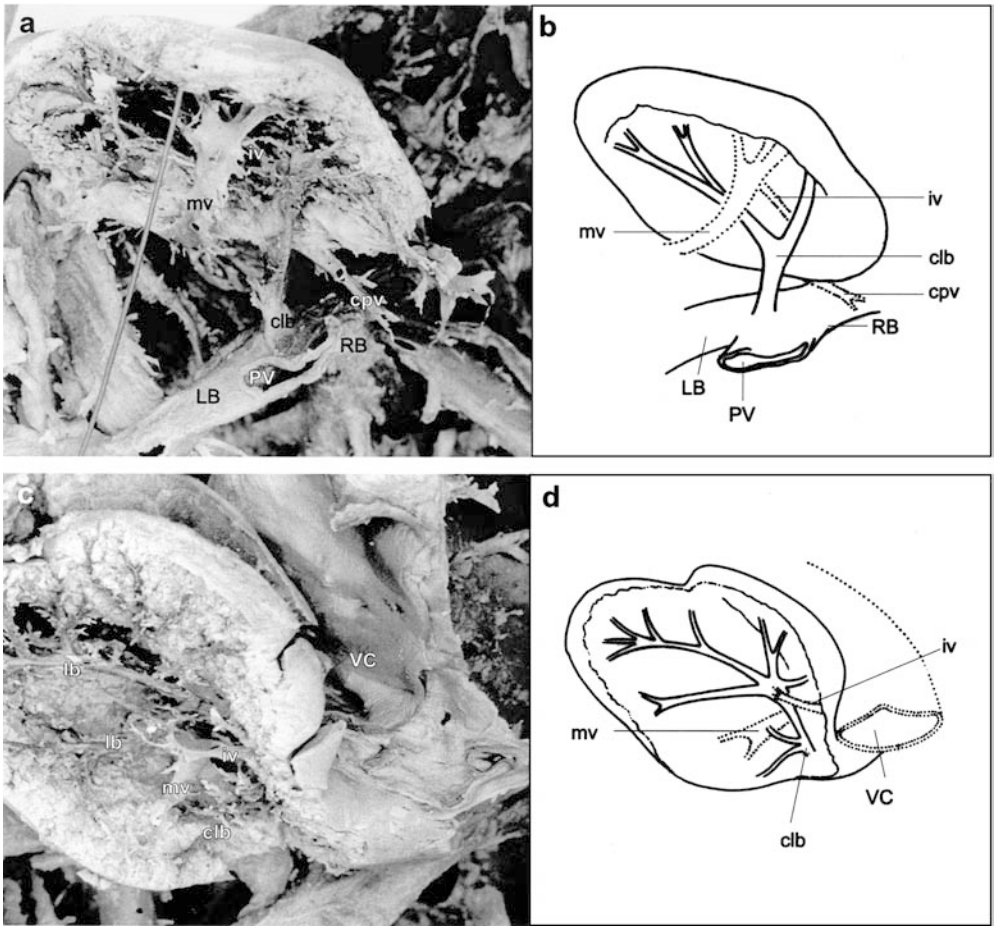

Fig. 2 The branch *(clb)* of the caudate lobe originates from the portal vein *(PV)* and bifurcates for distribution toward the anterior (**a, b**) and posterior (**c, d**) surfaces of the lobe and its papillary process. The variation observed in this case was that the portal ramifications were located deeply in relation to the middle caudate hepatic vein *(mv)* on the anterior surface and in relation to the inferior caudate vein *(iv)* on the posterior surface of the caudate lobe. (*cpv* vein of the caudate process; *LB*, *RB* left and right branches of PV; *clb* branch of the caudate lobe, *VC* inferior vena cava)

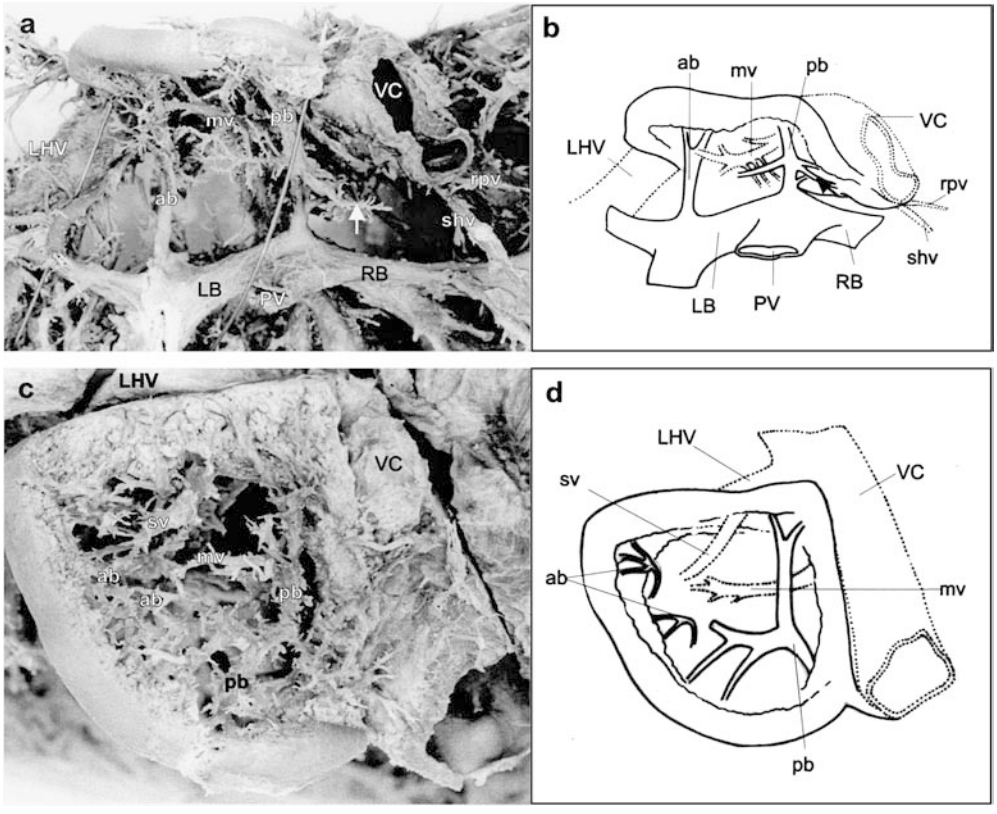

Fig. 3a–d The posterior *(pb)* and anterior *(ab)* caudate branches respectively originate from the portal vein *(PV)* and from its left branch *(LB)*. **a, b** They are respectively distributed toward the posterior and anterior surfaces of the caudate lobe, with the pb sending a branch *(arrow)* to the caudate process. The right vein of the caudate process *(rpv)* drains the right portion of the process and empties into the short hepatic vein *(shv)*. **c, d** As is normally the case, the middle caudate hepatic vein *(mv)* and the superior caudate vein *(sv)* are located deeply in relation to the portal ramifications, separating pb from ab. The mv empties into the inferior vena cava *(VC)* and, as a variation present in this case, the sv empties into the left hepatic vein *(LHV)* (*RB* right branch of PV)

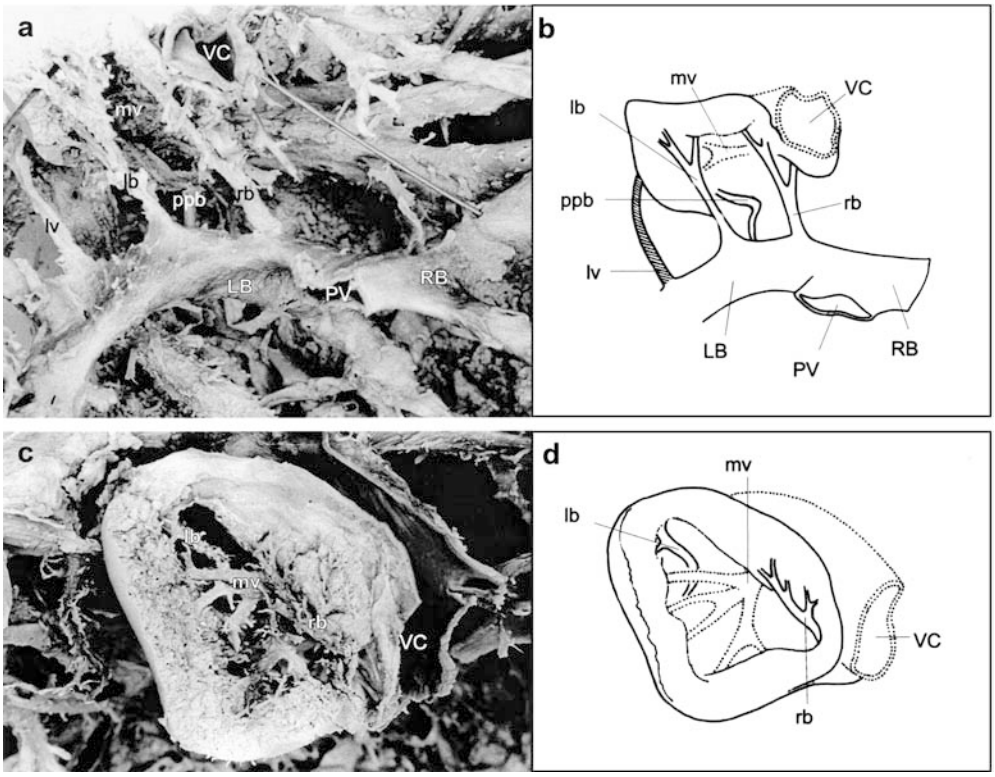

Fig. 4 a, b The right *(rb)* and left *(lb)* caudate branches of the caudate lobe originate from the left branch *(LB)* of the portal vein *(PV)* and supply the respective portions of the caudate lobe, with rb vascularizing the caudate process and lb the papillary process. The paracaval portal branch *(ppb)* originates from the LB, is directed at the S9 segment, and contributes to the vascularization of the anterior and superior portion of the caudate lobe. **c, d** The middle caudate hepatic vein *(mv)* separates the vascular beds of the two portal branches (*VC* inferior vena cava, *RB* right branch of PV, *iv* inferior caudate vein)

types; i.e., superior, middle. and inferior caudate veins, respectively.

In 13/40 (32.5%) cases, there was a vein for the drainage of the caudate lobe and papillary process, which was the middle caudate vein in 12/13 cases. In 19/40 (47.5%) cases, there were two veins for drainage, which were the middle and superior caudate veins in 10/19 cases. In 8/40 (20%) cases, there were all three caudate veins; i.e., the superior, middle, and inferior ones.

The middle caudate vein was present in 35/40 (87.5%) cases. The superior caudate vein was present in 23/40 (57.5%) cases, with two veins detected in 2/23. The inferior caudate vein was present in 16/40 (40.0%) cases. The superior, middle, and inferior caudate veins predominantly emptied into the respective portion of the left contour of the vena cava; i.e., areas 2, 6, and 10, respectively. Table 2 specifies the number, diameter, and emptying of the caudate hepatic veins and the distance from their ostia to the ostium of the common trunk of the intermediate and left hepatic veins.

The papillary process, considered separately, was drained by the middle caudate vein in 26/40 (65%) cases, by the inferior caudate vein in 12/40 (30%) cases, by the superior caudate vein in 1/40 (2.5%) cases, and by the middle and inferior caudate veins in 1/40 (2.5%) cases.

Portal branches towards the caudate process

According to the portal vascularization bed, three branches were found: right and left branches of the caudate process toward the respective part of the process, and a branch of the caudate process toward both parts of the process or its intermediate portion.

In 21/40 (52.5%) cases, the caudate process was vascularized by a single portal branch, which in

Table 1 Number, diameter (range and mean ± SD) and origin of the caudate portal branches for the caudate lobe and its papillary process, and relationship of these branches with the caudate hepatic veins (*chv*) (40 cases). (*LB*, *RB* left and right branches of the portal vein, respectively; *PV* portal vein; *chv* caudate hepatic veins; *Sf.*, *Sf.Ps*, *Sf.As* superficial branches on both surfaces and on the posterior and anterior surfaces of the lobe and its papillary process, respectively; *Deep* deep branches in relation to the hepatic veins)

Portal branch	Cases		Diameter (mm)		Origin			Relationship with the chv			
	n	%	Range	Mean ± SD	LB	PV	RB	Sf.	Sf.Ps	Sf.As	Deep
Caudate lobe branch	15	37.5	1.7–4.3	2.4 ± 0.6	9	6	–	11	3	–	1
Posterior caudate branch	20	50.0	1.2–3.2	2.1 ± 0.5	11	8	1	3	17	–	–
Anterior caudate branch	15	37.5	1.3–5.3	2.0 ± 1.0	12	2	1	5	–	9	1
Left caudate branch	14	35.0	1.0–2.8	1.8 ± 0.5	14	–	–	2	1	11	–
Right caudate branch	8	20.0	1.5–2.7	2.1 ± 0.4	2	3	3	1	7	–	–

Table 2 Number, diameter (range and mean ± SD), emptying of the superior, middle and inferior caudate hepatic veins and distance from their ostia to the ostium of the common trunk of the intermediate and left hepatic veins (40 cases). (*CT IHV-LHV* common trunk of the intermediate and left veins, *VC* inferior vena cava)

Caudate vein	Cases		Diameter (mm)		Ostia, diameter (mm)		Distance in mm between the ostia of the vein and those of CT IHV-LHV		Emptying into the VC area							
	n	%	Range	Mean ± SD	Range	Mean ± SD	Range	Mean ± SD	1	2	5	6	7	8	10	11
Superior	23	57.5	1.0–3.5	2.0 ± 0.6	1.2–4.7	2.1 ± 0.9	3.9–27.0	13.5 ± 6.9	1	11[a]	4	6	–	1[b]	–	–
Middle	35	87.5	1.2–7.3	4.0 ± 1.4	1.0–7.5	4.1 ± 1.6	8.6–47.0[c]	20.5 ± 7.2	–	1	–	24	3	–	6	1
Inferior	16	40.0	1.1–4.1	2.5 ± 0.8	1.2–4.9	2.4 ± 1.0	20.0–54.9	33.4 ± 8.7	–	–	–	2	–	–	13	1

[a]In one case there were two veins, one of which emptied into the intermediate hepatic vein
[b]In one case there were two veins, one of them emptying into area 8 and the other into area 10
[c]In one case there was no formation of a common trunk, and therefore we considered the mean distance to the ostia of the IHV and LHV

8/21 cases was the branch of the caudate process predominantly originating from the right branch of the portal vein. In 13/21 cases there was no special branch for the caudate process, which was vascularized by a branch that ran toward the caudate lobe, which in 6/13 cases was the posterior caudate branch. In 13/40 (32.5%) cases, the right branch of the caudate process vascularized the right portion of the process, whereas the left portion was vascularized by a branch of the caudate lobe proper, which was the posterior caudate branch in 7/13 cases. In 6/40 (15%) cases there were two branches particularly directed at the caudate process, one at the right portion and the other at the left portion. Thus, the right branch of the caudate process was present in 19/40 (47.5%) cases, and its most common origin was from the right branch of the portal vein; the left branch of the caudate process was present in 6/40 (15%) cases, and its most common origin (3/6 cases) was from the trunk of the portal vein.

Venous drainage of the caudate process

The veins that drained the caudate process or part of it were denominated as a vein of the caudate process when it drained the entire process, most of it, or only its intermediate portion; or as left and right veins of the caudate process when they partially or totally drained the respective portion. The right vein of the caudate process was present in 23/40 (57.5%) cases, with two veins being present in 1/23. In 16/23 cases, the vein emptied into the retrohepatic segment of the vena cava, predominantly (12/16 cases) into the inferior third of its anterior contour (area 11), and in 7/23 cases it was a tributary of the short hepatic vein, which emptied into the inferior vena cava. The vein of the caudate process was present in 15/40 (37.5%) cases and mainly emptied into area 11. The left vein of the caudate process was present in 12/40 (30%) cases, with three veins being detected in one case; this vein predominantly emptied into area 10 (the anterior inferior area of the inferior vena cava).

In 32/40 (80%) cases, one or more of the cited veins were present, and in 8/40 (20%) cases the process was drained by the caudate veins of the lobe, by the middle caudate vein in 5/8, and by the inferior caudate vein in 3/8 of these cases.

Paracaval segment

In 14/40 (35%) cases, there were paracaval branches originating from the portal vein or its branches and distributed toward the paracaval segment S9. These branches originated from the portal vein in 7/14 cases, from the right branch of the portal vein in 4/14, and from the left branch in 3/14. In 3/14 cases, in addition to the paracaval segment, they contributed to the vascularization of the right upper portion of the caudate lobe.

In 12/40 cases (30%), the caudate portal branches contributed to the vascularization of the paracaval segment S9. In 11/12 cases there was one branch, which was the right caudate branch in 4/11, the anterior caudate branch in 3/11, the left branch of the caudate process in 2/11, the right branch of the caudate process in 1/11, and the posterior caudate branch in 1/11. In 1/12 cases there was a contribution from two branches: the caudate lobe branch and the right branch of the caudate process.

With respect to the venous drainage of the paracaval segment (S9), in 12/40 (30%) cases there were 1–11 punctiform ostia measuring < 1.0 mm in diameter (minor hepatic veins) that emptied into the anterior and right contours of the retrohepatic segment of the vena cava.

Accessory caudate hepatic veins, tributaries of the left hepatic vein (LHV), intermediate hepatic vein (IHV), and common trunk IHV-LHV

In 11/40 (27.5%) cases, there were accessory caudate veins that were tributaries of the major hepatic veins, draining the upper third of the anterior surface of the caudate lobe in 10/11 cases and the middle third in 1/11 cases; their diameters were 1.0–1.5 mm, with a mean of

1.3 ± 0.2. In 8/11 cases they emptied into the IHV, with three veins being present in 1/8 cases; in 2/11 cases they emptied into the LHV, and in 1/11 cases there were two veins, one emptying into the IHV and the other into the common trunk IHV-LHV.

Discussion

Our results showed a wide variability of distribution of the caudate portal branches, as described by Laux and Rapp [10]. The portal vascularization of the caudate lobe and papillary process was mostly provided from a single branch (37.5% of cases), whereas other authors found predominantly two branches [10, 13] or three branches [3]. The portal vascularization was from a posterior branch and an anterior one in 27.5% of cases, and from a right branch and a left branch in 12.5% of cases. Only in 5/40 (12.5%) cases did we detect the portal ramification proposed by Minh et al. [12], i.e., an inferior right branch, a superior right branch, and a left branch. In the cases in which there was more than one branch, we considered the vascularization of the caudate lobe to be predominantly provided by the posterior and/or anterior branches, possibly complemented by the right and/or left branch. Heloury et al. [9] mentioned two left portal branches generally originating from the left branch of the portal vein and two right portal branches predominantly originating from the right branch and the trunk of the portal vein, and maybe another branch destined to the region of transition between the papillary and caudate processes. In the present study, however, we encountered mostly anterior and posterior branches because we used the nomenclature based on the territory of vascularization and not on the origin and direction of the branches. Minh et al. [12] described deep accessory portal branches in 80% of cases, which corresponded to the paracaval portal branches directed at the S9 segment described by Couinaud [4]. We detected them at a lower frequency, 35% of cases, and in 7.5% of them these branches contributed to the vascularization of the right upper portion of the caudate lobe. The portal vascularization of the caudate process was studied separately from the caudate lobe, and the presence of one or two branches responsible for its vascularization was observed, in agreement with the descriptions of Minh et al. [12]. The origin of the caudate portal branches detected here was predominantly from the left branch of the portal vein for the branches directed at the caudate lobe, and from the right branch of the portal vein for the branches directed at the caudate process, as also observed by most other authors [3, 9, 10].

In our results, we classified the hepatic veins of the caudate lobe and papillary process as superior, middle, and inferior. The frequency observed here was practically equal to that reported by Minh et al. [12] for the middle caudate vein (87.5% and 90%, respectively) and lower for the inferior caudate vein (40% and 86%, respectively). With respect to the superior caudate vein, it was not possible to compare our data with that reported by these authors because they considered this vein to belong to a single group together with the veins that emptied into the major hepatic veins, whereas we considered the latter separately as accessory caudate veins (5% of cases) that drained the anterior superior portion of the caudate lobe or even the middle part of its anterior surface. The frequency of accessory caudate veins that emptied into the left hepatic vein in our cases (5%) was lower than that reported by Laux and Rapp [10] (14%). We detected sites of emptying of caudate veins also in the intermediate hepatic vein and in the common trunk, at frequencies lower than those reported by Couinaud (6). These veins are very important in Budd-Chiari syndrome even though they are of small diameter, as observed in the present study, because a vein can increase its diameter three to four times.

The number of caudate hepatic veins ranged from one to three, and their frequencies were quite close to those reported by others authors [3, 13, 14]. However, Heloury et al. [9] found from one to nine, with a mean of four, probably owing to their consideration of the veins that drained the caudate process and the paracaval segment globally. A single hepatic vein drained the caudate lobe and papillary process in approximately 50% of cases [10, 11], a higher percentage than we observed (32.5%).

We agree with Minh et al. [12] with respect to the frequent interposition of the hepatic veins between the portal pedicles, which are located close to the posterior and anterior surfaces of the caudate lobe, except for 1/20 of our cases, in which the hepatic veins were superficial on the surfaces in relation to the caudate portal branches.

The drainage of the paracaval segment occurred through minor hepatic veins that emptied into punctiform ostia present in the anterior contour of the retrohepatic vena cava, as pointed out by Couinaud [4] and Laux and Rapp [10] when they referred to the minor foramina that emptied into the entire retrohepatic segment of the inferior vena cava, and by Masselot and Leborgne [11], who observed the presence of 8–20 small ostia always located below the ostium of the major caudate vein. Compared with a previous study [8] in which one of us investigated the portal branches in the hepatic hilus directed at the caudate lobe, we concluded that, to be sure that this branch actually is a caudate portal branch, it should also be dissected inside the caudate lobe; otherwise, it could be a paracaval portal branch.

For the classification of the emptying of the caudate hepatic veins into the vena cava, we divided the inner wall of the retrohepatic segment of the vena cava into 12 areas rather than into 16 areas as done by Chang et al. [2], who detected the emptying points in the left

anterior contour of the inferior vena cava, and by Camargo et al. [1], who detected them in the inferior 3/4 portion of the left half of the retrohepatic segment of the inferior vena cava. The latter authors found a middle ostium into which emptied two hepatic veins, the intermediate hepatic vein and the caudate vein. The present results, as well as those obtained by other authors [3, 4, 9, 12], show that the hepatic veins of the caudate lobe predominantly empty into the left contour of the retrohepatic segment of the portal vein (areas 2, 6, and 10), while the veins of the caudate process empty into the anterior contour of this segment (area 11).

Masselot and Leborgne [11] reported that the caudate veins empty at a distance of approximately 21 mm below the emptying of the common trunk of the intermediate and left hepatic veins. In the cases studied here, this distance was on average 13, 21, and 33 mm for the superior, middle, and inferior caudate veins, respectively.

Conclusion

The proposed new nomenclature of the caudate portal branches permitted a more precise analysis of the territory of distribution of these branches into segment I, separately from the vascularization of adjacent segments (segments IV, VII, and IX). The caudate portal branches were mostly situated superficially to the hepatic caudate veins. The detailed study of the caudate portal branches and of the caudate hepatic veins provides anatomical knowledge that requires special attention because of its value in diagnosing and treating liver diseases.

References

1. Camargo AMSR, Teixeira GG, Ortale JR (1996) Anatomy of the ostia venae hepaticae and the retrohepatic segment of the inferior vena cava. J Anat 188:59–64
2. Chang RWH, Shan-Quan S, Yen WWC (1989) An applied anatomical study of the ostia venae hepaticae and the retrohepatic segment of the inferior vena cava. J Anat 164:41–47
3. Couinaud C (1957) Le foie, études anatomiques et chirurgicales. Masson, Paris
4. Couinaud C (1994) The paracaval segments of the liver. J Hep Bil Pancr Surg 2:145–151
5. FCAT—Federative Committee on Anatomical Terminology (1998) International anatomical terminology. Thieme, New York
6. Di Dio LJA (1982) Segments of the liver, anatomical basis for partial hepatectomy. In: Motta PM, DiDio LJA (eds) Basic and clinical hepatology. Martinus Nijhoff, The Hague
7. Elias H, Sherrick JC (1969) Morphology of the liver. Academic Press, New York
8. Franceschini L, Ortale JR (1995) Ramification of the portal vein at the porta hepatis in humans. Surg Radio Anat 17:35–39
9. Heloury Y, Leborgne J, Rogez JM, Robert R, Barbin JY, Hureau J (1988) The caudate lobe of the liver. Surg Radio Anat 10:83–91
10. Laux G, Rapp PE (1953) Le dispositif veineux du lobe de Spigel. CR Assoc Anat 78:264–271
11. Masselot R, Leborgne J (1978) Anatomical study of the hepatic veins. Anat Clin 1:109–125
12. Minh Tv, Galizia G, Lieto E (1992) L'anatomie du lobe de Spiegel du foie. Aspects nouveaux et applications chirurgicales. Ann Chir 46:309–318
13. Mizumoto R, Suzuki H (1988) Surgical anatomy of the hilum hepaticum with special reference to the caudate lobe. World J Surg 12:2-10
14. Nakamura S, Tsuzuki T (1981) Surgical anatomy of the hepatic veins and the inferior vena cava. Surg Gynecol Obstet 152:43–50
15. Our Q-J, Hermann Re (1984) The role of hepatic veins in liver operations. Surg 95:381–391